



Botulinum toxin A for the treatment of lateral periorbital rhytids

David W. Kim, MD^{a,*}, Jason Cundiff, MD^b, Dean M. Toriumi, MD^b

^a*Division of Facial Plastic and Reconstructive Surgery, Department of Otolaryngology—Head and Neck Surgery, University of California, San Francisco, 400 Parnassus Avenue A-730, San Francisco, CA 94143-0342, USA*

^b*Division of Facial Plastic and Reconstructive Surgery, Department of Otolaryngology—Head and Neck Surgery, University of Illinois at Chicago, 1855 West Taylor Street, Chicago, IL 60612, USA*

One of the first signs of aging is the formation of lateral periorbital rhytids, or crow's feet. Depending on the individual's skin type, muscle activity, and previous sun exposure, these lines may begin to appear as early as 20 years of age. As a result of the frequent and repeated contraction of the periorbital muscles with smiling, closing the eyes, and so forth these lines become increasingly noticeable with time. Although these lines may initially appear only during animation, they eventually become a permanent feature of the skin. As such, this area is often identified as a problem area for patients who seek facial rejuvenation.

The inherent thinness and abundance of skin lateral to the orbit makes it prone to rhytid formation. Correction of this skin laxity is the goal of many traditional treatment modalities, such as lifting procedures, resurfacing, or augmentation. As with rhytids in all facial regions, the formation of crow's feet results from muscle activity and inherent skin properties. Unless the dynamic muscular contribution to rhytid formation is addressed as well as the skin, the effects of treatment are likely to be incomplete and short-lived.

The application of botulinum toxin A (Botox) safely denervates targeted muscles that contribute to the formation of hyperfunctional facial lines. The selective flaccid paralysis effectively eliminates the distortion or pull on the skin by the underlying mus-

cles. The effect, although temporary (3 to 6 months), is achieved through a safe, reliable, and minimally invasive office procedure.

Anatomy

An understanding of the lateral periorbital muscles is crucial for the treatment of lateral periorbital rhytids. Contraction of the orbicularis oculi, risorius, and zygomaticus muscles gives rise to the formation of crow's feet. Selective denervation of the lateral orbital portion of the orbicularis oculi will most effectively treat this area. The orbicularis oculi is a large, circular band of muscle that consists of two components: the orbital and palpebral portions. The orbital portion originates on the anterior aspect of the inferior and superior orbital rim and is responsible for tight eye closure and depressing the brow. The muscle encircles the periorbital region and inserts on the medial and lateral canthal tendons, frontalis, procerus, corrugator supercilii, and superficial temporal fascia. The palpebral portion of the orbicularis oculi provides the sphincteric action of the eyelid and is responsible for blinking and gentle eyelid closure. This area should be avoided during Botox injection because it can result in loss of sphincteric function and voluntary eye closure. The palpebral orbicularis is divided into a preseptal and pretarsal region. The preseptal portion overlies the orbital septum and arises from the medial canthal tendon and aids the lacrimal pump mechanism. The pretarsal portion overlies the tarsal plate. The upper and lower pretarsal muscles join to form the lateral

* Corresponding author. UCSF Facial Plastic and Reconstructive Surgery, 2330 Post Street, 5th Floor, San Francisco, CA 94115.

E-mail address: dKim@ohns.ucsf.edu (D.W. Kim).

canthal tendon. Rounding of the lateral canthus can result from paralysis of the lateral canthal tendon with Botox injection. The orbicularis oculi is supplied by the facial and superficial temporal arteries from the external carotid artery, and the dorsal nasal, supra-trochlear, supraorbital, and lacrimal arteries from the internal carotid artery. The orbicularis oculi is innervated mainly by the temporal branch of the facial nerve with minor contributions from buccal and zygomatic branches of the facial nerve (Fig. 1) [1–3].

The zygomaticus major arises anterior to the zygomaticotemporal suture deep to the orbicularis oculi and inserts onto the skin and mucosa of the mouth. The zygomaticus major moves the angle of the mouth superior, lateral, and posterior with laughing, smiling, and chewing. This muscle should be avoided during Botox injection because it can result in lateral lip paralysis and drooping of the oral commissure. The zygomaticus minor arises from the zygomatic bone below the infraorbital rim and inserts to the upper lip. The zygomaticus minor elevates the central upper lip and nasolabial fold. The risorius arises from the masseter fascia and inserts at the corner of the mouth. Contraction of the zygomaticus and risorius muscles enhances the radially-oriented folds of the lateral canthus which results in the formation of crow's feet. The levator labii superioris arises below the infraorbital rim and passes deep to the zygomaticus muscles to insert at the angle of the mouth. Levator labii superioris paralysis from Botox injection can result in lengthening of the upper lip. The temporalis muscle arises from the floor of the temporal fossa and inserts to coronoid process and anterior ramus of the mandible [2,3].

The lateral orbital wall is formed by the zygoma, the greater wing of the sphenoid, and the frontal bone superiorly. The sphenoid forms the posterior portion of the lateral orbit wall and separates the orbit from the middle cranial cavity. The lateral palpebral ligament attaches the eyelids to the lateral margin of the orbit. The lateral rectus arises from the common tendinous ring at the apex of the orbit and inserts on the globe 6 mm to 8 mm posterior to the limbus of the globe. Lateral rectus palsy is a potential complication from Botox injection for crow's feet. This can be avoided by injecting more than 1.0 cm lateral to the lateral bony margin or the orbit [2,3].

The superficial arterial supply of the lateral orbit consists of the superior and inferior palpebral arteries. The superficial temporal artery is also located in this region just superior and lateral to the orbit and can be palpated in most patients. An extensive network of superficial venous structures surrounds the eyelid. Laterally, this consists of anastomoses between superior and inferior palpebral veins. These arteries and veins lie just superficial to the orbicularis oculi and should be avoided by limiting the depth of injection to the subcutaneous layer, [2,3].

Other methods of therapy

Several alternative techniques for the treatment of crow's feet exist. These include resurfacing procedures, augmentation with implants, and surgical procedures.

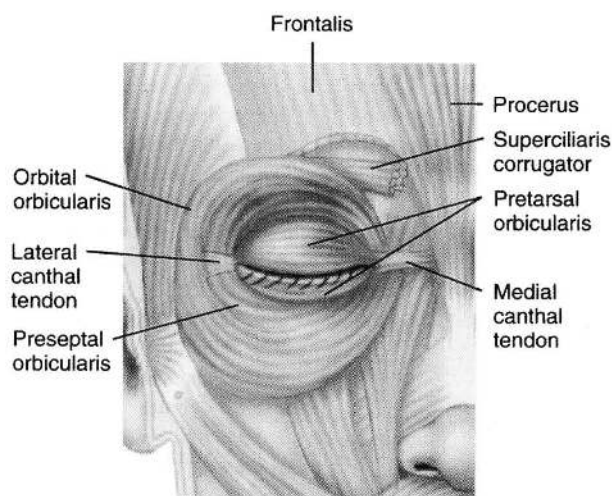


Fig. 1. Periorbital anatomy.

Skin resurfacing may be accomplished with lasers, chemical peels, dermabrasion, or phototherapy. Depending on the depth of skin injury, these methods may lead to the improvement of actinically-damaged or aged skin through the formation of new collagen and epidermal elements. These methods do not address the muscle contribution to rhytid formation. In addition, resurfacing procedures pose the additional risks of scarring, herpetic outbreak, and hyper- or hypopigmentation.

Augmentation techniques include subcutaneous placement of injectable fillers. Collagen implants autologous fat, and acellular dermis (Cymetra, Life Cell, Branchburg, NJ) represent materials that will reabsorb over time after the procedure. These methods of augmentation will partially efface rhytids by stretching the involved skin through the expansion of the underlying subcutaneous space. Again, these techniques do not influence muscle function. Additionally, augmentation may create an unnatural over-enlarged appearance and create a risk of immediate or delayed infection.

Extended upper lid blepharoplasty, various forms of brow lifting, and forehead lifting have all been described as methods to improve crow's feet. Although these techniques may reduce the amount of redundant cutaneous tissue in the lateral periorbital region, muscle activity is not addressed. In addition, the incisions are typically removed from the lateral periorbital region itself. Therefore, the action on the crow's feet skin is an indirect one, which is transmitted through the pulling of a variable segment of intervening skin. For upper blepharoplasty, to gain adequate tension on the lateral periorbital region, the incision must be extended fairly laterally into a more cosmetically conspicuous area. Finally, these techniques are performed predominantly to address excessive upper lid skin and fat. As such, they are inappropriate for the treatment of rhytids isolated to the lateral periorbital area.

Various techniques to surgically alter the lateral periorbital musculature in aims of reducing the dynamic component of crow's feet formation have been described. Skoog [4] advocated a facelift approach with suture fixation of the lateral aspect of the orbicularis oculi into a maximally splayed position to smooth the overlying skin at the lateral canthus. Aston [5] reported an increased effectiveness of this procedure in patients who have thick muscle and larger lateral skin folds when the lateral aspect of the muscle was divided before suture suspension. Although these procedures have the theoretical advantage of addressing the muscular and cutaneous etiologies of crow's feet, they incur greater risks of complications of facial nerve injury, asymmetry,

visible scarring, and impairment to the sphincteric function of the orbicularis oculi muscle.

Technique

On initial consultation, the new patient must be informed of the delayed and transient nature of the effect of Botox, as well as potential complications. Returning patients should be questioned about the effectiveness and durability of previous treatments. Based on this feedback, the operator may be able to fine tune the technique to improve results. New patients should undergo a complete history to rule out neuromuscular disorders or the use of aminoglycoside antibiotics.

Before injection, the patient must be evaluated thoroughly. Most patients will present with a need for injection into several facial muscle groups, in addition to the lateral periorbital area. The patient should be questioned about the areas that are most concerning so that treatment may be customized to individual need. The quality of skin over the lateral periorbital area must be inspected and palpated. The thickness and elasticity must be considered to gauge the appropriate depth of needle penetration. Skin laxity should alert the operator that muscle denervation may not be adequate to address the cause of the crow's feet. In such cases, the skin may also need to be addressed with an adjuvant procedure, such as chemical peel or laser resurfacing. The depth and number of lateral periorbital rhytids should be noted with the patient at rest and while squinting. A larger dose of Botox may be needed in individuals who have exuberant animation or usually prominent lateral periorbital musculature. Finally, extraocular motion, lid closure, and facial nerve function should be assessed to establish a baseline before the procedure.

Generally, the patient is seated in an examination chair and instructed to apply an ice pack or cold pack over the proposed injection sites for 10 minutes before the procedure. Topical anesthetics may be applied to reduce the discomfort, but are typically not necessary. The total dose of Botox that is applied to each lateral crow's feet area varies from 5 to 15 units, depending on the severity of rhytids and muscle activity. Because the skin is thin in this region, a low volume, high concentration dilution may be desired (eg, 30 units per mL which is prepared by adding 3.3 mL of saline to a 100 unit vial).

Because of the thin skin and superficial location of blood vessels in this region, bruising is a common complication. To avoid this, a 30 gauge needle is used on a 1 mL tuberculin syringe. Avoiding direct intra-

muscular injection decreases the likelihood of hematoma. Injection into the subcutaneous space seems to allow for diffusion of the toxin into underlying muscle.

The number and spacing of injections depends on the density and depth of the rhytids. On average, injections may be spaced 5 mm to 10 mm apart in the areas of troublesome muscle movement and obvious crow's feet. Injections should be placed lateral to the lateral orbital rim to decrease the risk of diffusion to the lateral rectus or pretarsal portion of the orbicularis oculi. The patient should be instructed to squint between injections to ensure that treatment is appropriately individualized. In all, three to eight injections may be required on each side (Fig. 2).

Unless a change in brow position is desired, the injections should terminate at least 1 cm below the eyebrow. Injection just below the tail of the eyebrow may result in lateral brow elevation, particularly if strong frontalis activity is also present. Similarly, injections in this region should remain above the zygomatic arch. Inferior migration of toxin was reported to cause lip ptosis, presumably from weakening of the zygomaticus major muscle.

Postprocedure

The patient is instructed to keep firm pressure and a cold pack or ice over the injected area for at least 10 minutes immediately after the procedure. The patient should understand that bruising may occur over the area and will resolve over several days. The initial effects of therapy may be discerned 2 to 3 days after treatment, but maximal improvement will take up to 2 weeks to occur. The patient should be instructed to contact the operator for delayed bruising, diplopia, lagophthalmos, headaches, or other muscle weakness. There are no major limitations to activity following the procedure.

Botox as adjuvant therapy

Botox may be combined with surgical techniques (blepharoplasty, brow lifts, and other face lifting techniques) as adjuvant therapy to address crow's feet in the aging face. In such cases, Botox enhances the treatment of crow's feet because these procedures do not address the true etiology—the contraction of the orbicularis. Some investigators suggested that direct injection of Botox into the undersurface of the orbicularis oculi muscle during surgery creates a more durable denervation than with transcutaneous injection [6].

Others have advocated a role for intraoperative Botox to improve scar formation. Sherris and Gassner [7] conducted a primate study in which forehead incisions were randomly injected with Botox or 0.9% saline. The incisions were blindly reviewed by three observers, who noted significantly decreased scarring in the incisions that were injected with Botox. In this case, Botox paralyzed the muscles beneath the incisions which decreased the tension on the healing areas and improved the overall scar results.

The use of Botox pretreatment on laser resurfacing results has also been studied in a randomized, blinded trial. Ten patients were enrolled in this study; pretreatment with Botox contributed to significant improvements in laser resurfacing results in the crow's feet region [8].

Results

Numerous authors have described the successful treatment of crow's feet by Botox [9–12]. Upon review of the literature, the successful use of Botox to treat crow's feet was reported in more than 500 cases. Most articles reported the success rate of Botox to treat crow's feet to be 95% to 100% with an

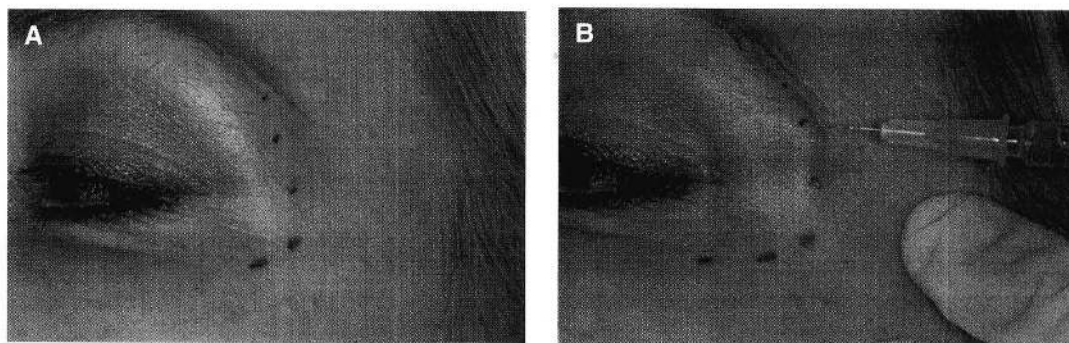


Fig. 2. (A) Patient with typical markings for injection. (B) Injection of Botox.

average duration of 3 to 6 months. Garcia and Fulton [13] reported the successful use of Botox to treat crow's feet in a large study that involved 183 patients. They conducted a dose-response study, which showed that only one to two units of Botox were required per injection site. They also found no change in Botox potency after refrigerator storage for 30 days. They reported the following complications: 15% of patients demonstrated bruising at injection site, 5% of patients developed ptosis of the lateral eyebrow, there was one case of temporary zygomaticus major muscle paresis, and one case of diplopia for a 3-week duration [13]. A double-blind randomization that compared botulinum toxin type A with botulinum toxin type B in the treatment of crow's feet in 10 patients was reported by Matarasso [14]. Type A and B botulinum toxins were effective in reducing crow's feet with no difference in outcome; however, type B toxin was associated with slightly more discomfort, quicker onset of action, and a briefer duration of muscle paralysis [14].

Pitfalls

Ecchymosis at the injection site is the most common complication; nearly 15% of patients experience some bruising [13]. Bruising usually resolves in 10 days and can be avoided by injecting into the subcutaneous layer and avoiding the vasculature superficial to the orbicularis oculi.

Lateral brow ptosis was reported to occur in nearly 5% of patients who were injected with Botox for crow's feet [13]. This occurs with lateral frontalis denervation because the injections are applied superior to the appropriate field. This can be avoided by staying below the eyebrow.

Lateral rectus palsy is a potential complication of Botox injection for crow's feet. There is one reported case of diplopia after Botox injection for crow's feet, which resolved after several weeks [13]. This was likely due to injection too medial and deep, leading to diffusion of Botox into the area of the lateral rectus,

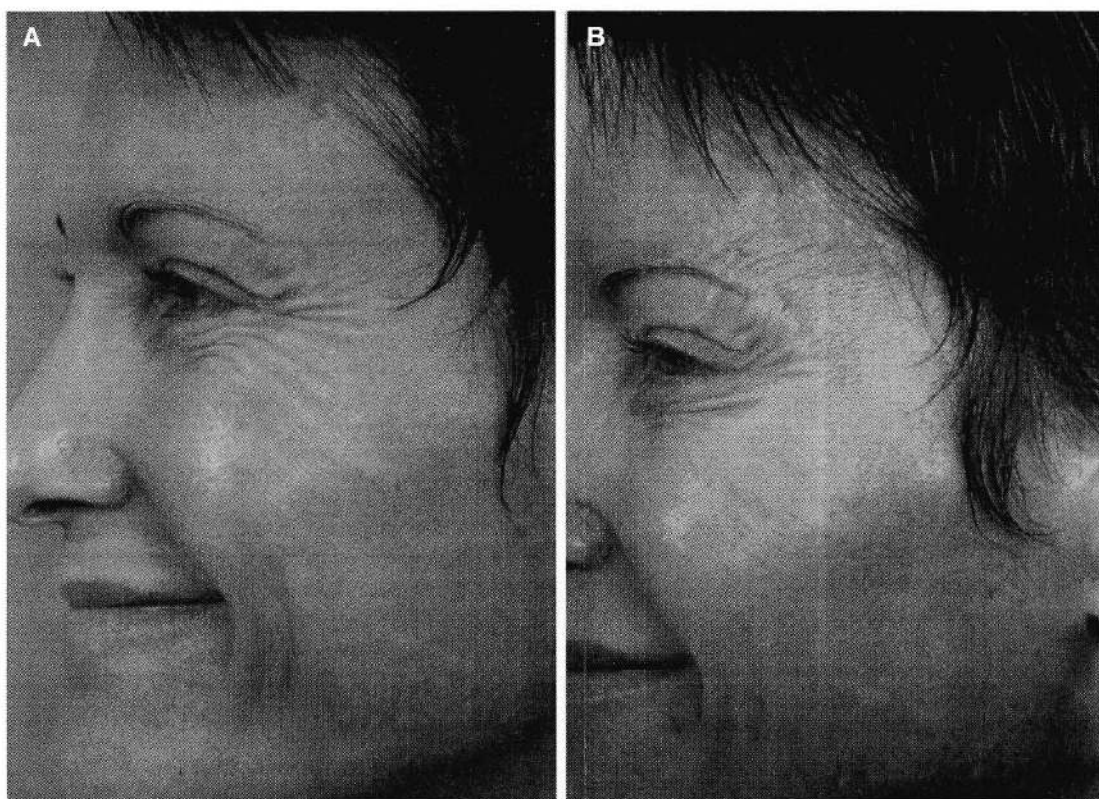


Fig. 3. (A) Appearance of crow's feet before Botox injections. (B) 1 month post-Botox to lateral periorbital musculature.

causing palsy of this muscle. Should diplopia occur, patching the affected eye or attaching a Frensel membrane prism to eyeglasses will resolve the problem until the lateral rectus recovers. This can be avoided by injecting lateral to the lateral orbital rim and applying digital pressure onto the rim after injection.

Zygomaticus major palsy can result in lip drop after Botox injection for crow's feet. Four cases of zygomaticus major palsy have been reported in the literature [13,15]. Matarasso and Matarasso [15] reported three of these cases and speculated that this complication was related to intraoperative injection and modified periocular tissue planes that allowed Botox migrations to occur. Upon review of this article, however, Fagien [16] suggested that these complications were likely related to injecting Botox too deep or to diffusion of the Botox. Limiting inferior injection to the superiormost aspect of the zygomatic arch and avoiding deep injections can avoid this complication.

Loss of sphincteric function of the orbicularis oculi muscle and voluntary eye closure can result from paralysis of the palpebral portion of the orbicularis oculi. Patients who have an attenuated orbital septum are more susceptible to this complication. Ptosis can be avoided by injecting lateral to the lateral orbital rim. If needed, Apraclonidine 0.5% eyedrops, an α_2 -adrenergic agonist, can be used to treat Botox-induced ptosis. This agent causes Müller's muscle to contract, which partially counteracts the loss of levator function. Phenylephrine (Neo-Synephrine) 2.5% can be used as an alternative in patients who have sensitivity to apraclonidine. Neo-Synephrine is contraindicated in patients who have narrow-angle glaucoma and in patients who have aneurysms. Drops should be used three times daily until ptosis resolves [17].

Rounding of the lateral canthus can result from paralysis of the upper and lower pretarsal muscles of the orbicularis oculi. This can be avoided by injecting lateral to the lateral orbital rim. All complications are temporary; no long-term complications have been reported in the use of Botox for the treatment of crow's feet

Summary

The lateral periorbital area represents one of the earliest and most bothersome facial stigmata of aging. Although traditional techniques have had limited success in treating the static cutaneous component to rhytid formation in this region, they have been largely unsuccessful in addressing the dynamic hyperkinetic lines that are created by the activity of the

lateral orbicularis oculi muscle. Botox A injection represents a safe and reproducible technique to selectively denervate muscle activity in this troublesome area. This minimally invasive technique has led to significant improvement of periorbital lines, either when used as a single agent or in combination with other methods (Fig. 3). As more experience is gained with this toxin, as well as other Botox serotypes, continued progress is likely to occur in this area, as well as in other facial regions.

References

- [1] Wieder JM, Moy RL. Understanding botulinum toxin: surgical anatomy of the frown, forehead, and periocular region. *Dermatol Surg* 1998;24:1172–4.
- [2] Doxanas MT, Anderson RL. *Clinical orbital anatomy*. Baltimore (MD): Williams & Wilkins; 1984.
- [3] Zibe BM, Jelks GW. *Surgical anatomy of the orbit*. New York: Raven Press; 1985.
- [4] Skoog T. *Plastic surgery*. Philadelphia: Saunders; 1975.
- [5] Aston SJ. Orbicularis oculi muscle flaps: a technique to reduce crows feet and lateral canthal skin folds. *Plast Reconstr Surg* 1980;65:206–16.
- [6] Guerrissi JO. Intraoperative injection of botulinum toxin A into orbicularis oculi muscle for the treatment of crow's feet. *Plast Reconstr Surg* 2000;104(6):2219–25.
- [7] Sherris DA, Gassner HG. Botulinum toxin to minimize facial scarring. *Facial Plast Surg* 2002;18(1):35–9.
- [8] Zimbler MS, Holds JB, Kokoska MS, Glaser DA, Prendiville S, Hollenbeak CS. Effect of botulinum toxin pretreatment on laser resurfacing results: a prospective, randomized, blinded trial. *Arch Facial Plast Surg* 2001;3(3):165–9.
- [9] Guerrissi J, Sarkissian P. Local injection into mimetic muscles of botulinum toxin A for the treatment of facial lines. *Ann Plast Surg* 1997;38:447–53.
- [10] Keen M, Blitzer A, Binder WJ, Aviv JE, Keen MS, Brin MF. Botulinum toxin A for hyperkinetic facial lines: results of a double-blind, placebo-controlled study. *Plast Reconstr Surg* 1994;94(1):94–9.
- [11] Blitzer A, Binder WJ, Aviv JE, Keen MS, Brin MF. The management of hyperfunctional facial lines with botulinum toxin: a collaborative study of 210 injection sites in 162 patients. *Arch Otolaryngol Head Neck Surg* 1997;123(4):389–92.
- [12] Lowe NJ, Lask G, Yamauchi P, Moore D. Bilateral, double-blind, randomized comparison of 3 doses of botulinum toxin type A and placebo in patients with crow's feet. *J Am Acad Dermatol* 2002;47(6):834–40.
- [13] Garcia A, Fulton JE. Cosmetic denervation of the muscles of facial expression with botulinum toxin. *Dermatol Surg* 1996;22:39–43.
- [14] Matarasso SL. Comparison of botulinum toxin types A and B: a bilateral and double-blind randomized evalua-

- tion in the treatment of canthal rhytids. *Dermatol Surg* 2003;29(1):7–13.
- [15] Matarasso SL, Matarasso A. Treatment guidelines of botulinum toxin type A for the periocular region and a report on partial upper lip ptosis following injections to the lateral canthal rhytids. *Plast Reconstr Surg* 2001;108(1):208–14.
- [16] Fagien S. Treatment for botulinum toxin type A for the periocular region and a report on partial upper lip ptosis following injections to the lateral canthal rhytids - discussion. *Plast Reconstr Surg* 2001;108(1):215–7.
- [17] Hauser RA, Wahba M. Botox injections. In: Paletta C, editor. *Ancillary procedures, plastic surgery, emedicine*; 2002. Available at: <http://www.emedicine.com/plastic/topic509.htm>. Accessed March 1, 2003.