

June 2011

Implant

DENTISTRY TODAY

Earn four hours of verifiable CPD with this issue

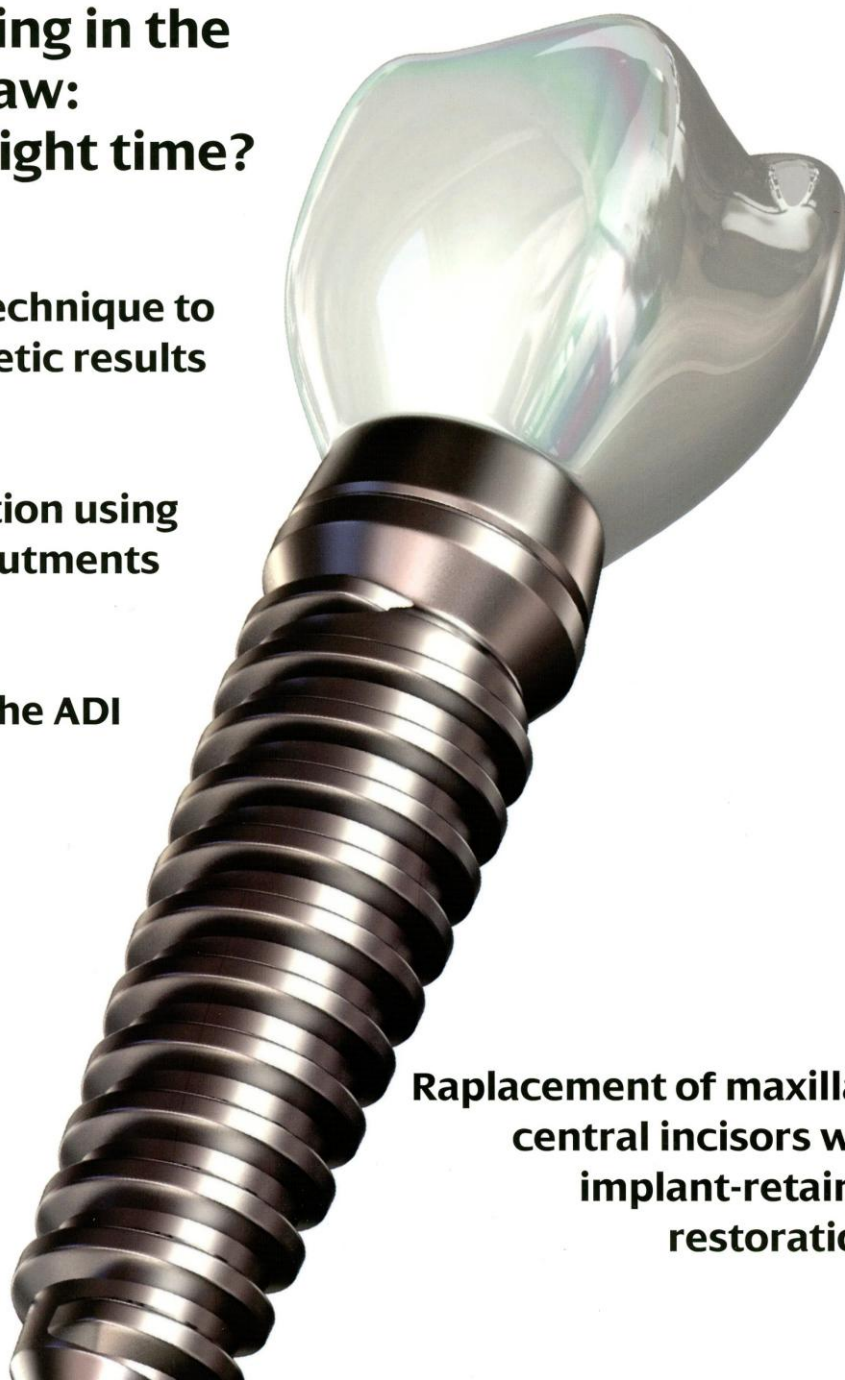
Implant loading in the edentulous jaw: when is the right time?

Simple surgical technique to maximise prosthetic results

Full arch restoration using computerised abutments

Major review of the ADI conference

Replacement of maxillary central incisors with implant-retained restorations



Full arch restoration using computerised abutments

Dean C Vafiadis presents a case report where treatment of an edentulous patient involved the placement of eight implants and immediate restoration

Immediate placement of endosseous implants has become a predictable technique for many patients (Liu CLS, 2005; Ganeles J et al, 2001; Romanos GE, 2003; Jaffi RA, Kumar A, Berman CL, 1996).

After the implants have been placed, many factors need to be evaluated for the fabrication and design of the provisional restoration. Critical factors in the fabrication of such a provisional include: torque value, stability of implants, arch-form, occlusion, opposing dentition, implant type, anterior-posterior (A-P) spread, facial aesthetics, lip form and evaluation of the buccal corridor (Sullivan DY et al, 1996; Tarnow DP, Emtiaz S, Classi A, 1997; Saadoun AP, 2004; Salama H et al, 1945; Hunt P, Ararat Y, 2006).

During implant rehabilitation, many steps and procedures have to be successfully accomplished to restore a full arch dentition in a timely fashion.

All of the preliminary surgical diagnostic steps – radiographs, wax-ups and dental scans – comprise the necessary surgical checkpoints to provide a successful surgery. For the restorative dentist, the most important of these is the diagnostic wax-up. Because many patients present with existing dentures, this step often gets overlooked. A full denture set-up will be necessary at some point, so the clinician should try to fabricate this wax-up as soon as possible so that, even before the surgical procedures, all the facial aesthetics


Aims and objectives

The aim of this article is to demonstrate the placement of eight implants and immediate restoration in a fully edentulous patient using computerised abutments.

The reader will:

- Appreciate all of the preliminary surgical diagnostic steps that comprise the necessary checkpoints to achieve success
- Follow a case study of a 45-year-old edentulous smoker
- Learn about the procedures involved in fabricating computerised abutments.

Implant Dentistry Today subscribers can answer the CPD questions on page 62 to earn one hour of verifiable CPD from reading this article.



Figures 1 and 2: The vertical dimension of occlusion had collapsed



Dean C Vafiadis, DDS, is a prosthodontist who maintains a cosmetic and implant practice in Manhattan, New York. He is currently the director of the full-mouth rehabilitation CE course at New York University (NYU). He is also an associate professor of prosthodontics at NYU College of Dentistry. Dr Vafiadis is a lecturer and clinical instructor on the Aesthetic Advantage Course in the Rosenthal Institute of Aesthetic and Implant Dentistry at NYU.

and phonetic considerations have already been addressed. Also, a surgical stent can be fabricated from this wax-up and an incisal position index may be used for scanning radiographs.

Case study

This 45-year-old male had been edentulous for four years and was a smoker. Facial aesthetics had been compromised with the original denture. The lack of lip support was evident. The vertical dimension of occlusion

had collapsed (Figures 1 and 2). The denture had undergone many repairs as a result of compromised occlusion, and the teeth were too short and did not enhance his face. The ridge architecture was normal and the bony hard tissue available for implants. Bone and gingival evaluation was performed intra-orally with dental scans.

For this patient, the plan was to place eight implants with immediate restoration in order to establish cross-arch stabilisation with the interim prosthesis. The original

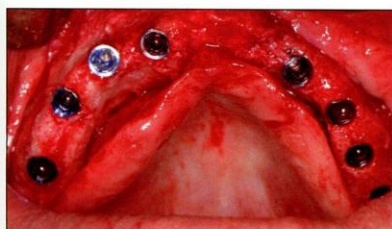

Figure 3: Eight NanoTite Certain implants were placed in ideal positions

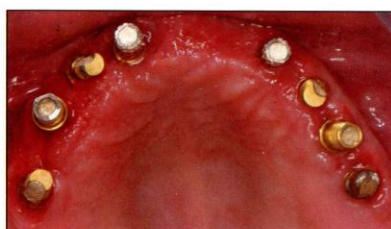

Figure 4: The palatal and posterior portion of the denture was removed

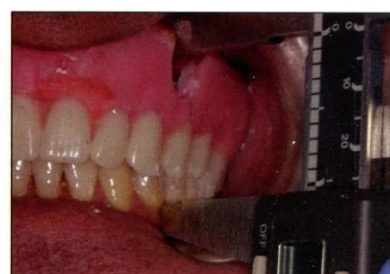

Figure 5: VDO verification will determine the final vertical dimension of occlusion

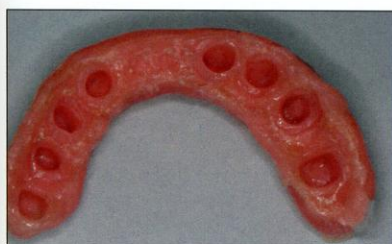

Figure 6: Using additional acrylic on the maxillary canines can ensure that the patient has canine guidance and posterior disocclusion in working movements

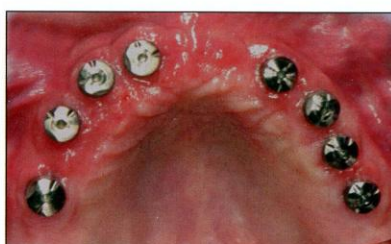

Figure 7: Encode healing/coded abutments were placed

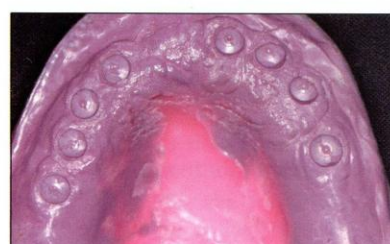


Figure 8: Final impressions of the Encode abutments were made

prosthesis would be used for the provisional, over provisional abutments that would be cement-retained. Using endosseous internal hexed implants (NanoTite Certain, Biomet 3i) and interim provisional abutments at the time of surgery facilitated the treatment, resulting in an efficient sequence with very minimal post-operative pain and swelling. In addition, it gave the patient confidence in chewing and socialising that had been lost when his teeth were originally removed. Regardless of the type of interim prosthesis – immediate fixed restoration, original denture or immediate denture – the provisional restoration must be fabricated following consideration of:

1. Facial aesthetics
2. Central tooth position
3. Restoration of the vertical dimension of occlusion (VDO)
4. Right side/left side dominance
5. Phonetics and lingual position
6. Smile line
7. Buccal corridor and lip support.

All of these factors play a critical role in the fabrication of the final implant-supported prosthesis, laboratory framework and final facial aesthetics. Without addressing these factors, the prosthesis may be short vertically with a lack of tooth support for the facial muscles and lips. The prosthesis will look artificial, and the occlusion will be compromised.

Procedure

A surgical full thickness flap for visibility and true analysis of hard tissue was performed. Eight NanoTite Certain implants were placed in ideal positions (Figure 3). This placement, although guided by pre-surgical scans, still resulted in 12° to 15° offset. Four 15° provisional abutments were used. Gold screws were used and tightened to 20Ncm with a torque driver. The palatal and posterior portion of the denture was removed (Figure 4).

Note: if the placement of the implants had been greater than 20° in divergence, it would have been impossible to cement the prosthesis onto the implant abutments, and the prosthesis would have had to be screw-retained.

VDO verification

After the denture was prepared, a VDO verification had to be made before relining the provisional restoration. Two reference points were chosen – one in the maxillary arch and one in the mandibular arch.

For example, the cervical area at the gingival margin from implant position UL3 and the CEJ gingival margin of tooth LL3 were chosen arbitrarily. (Multiple reference points can be chosen to have more predictable repeated measurements.) These measurements were made with a digital calliper, which

immediately displayed the distance in millimetres or inches. This tool meets the need for accuracy and takes into account patient variability. A single transverse horizontal axis can usually be located (Preston JD, 1979; Ortial JP, 1995). These measurements are based on facial aesthetics, phonetics, anterior tooth position and mandibular freeway space from the diagnostic denture. It is these measurements, when repeated intra-orally, that determine the final vertical dimension of occlusion (Figure 5).

Provisionalisation

Before relining the provisional, these measurements were confirmed. The remaining denture was relined with self-cured acrylic over the provisional abutments. Previous protocols described by Tarnow et al (1997) were used. After relining, the provisional was removed, trimmed and polished. Centric occlusion and maximum intercuspation was corrected, and canine guidance was established. Using additional acrylic on the maxillary canines can ensure that the patient has canine guidance and posterior disocclusion in working movements (Figure 6). The prosthesis was cemented with IRM cement (3M EPSE) and not removed for three months.

After four months, the provisional was removed and evaluation of the osseointegration

of the implants was performed with the reverse torque technique. A new impression of the edentulous ridge and fabrication of a wax rim was made during the healing phase.

Six months after implant placement, the implants were exposed with a non-surgical laser technique (Waterlase, Biolase) and Encode (Biomet 3i) healing/coded abutments were placed (Figure 7).

Final impression

Final impressions of the Encode abutments were made (Figure 8) and the provisional was relined over these abutments. Accurate capture of 3mm beyond the tissue and all the codes of the Encode abutments is a required criterion for success with this technique. Models were poured and mounted and ready for scanning.

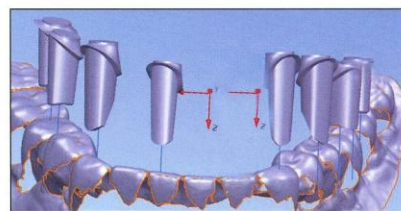
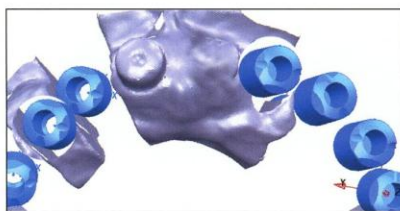Computerised abutments

An optical light scanner was used to capture all of the information provided by the Encode abutments. This information was used to design a perfect abutment for the prosthesis.

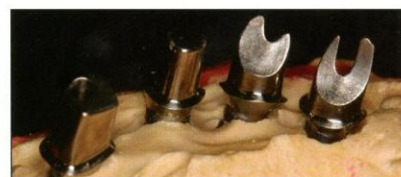Marginal placement of the facial and lingual gingival heights was determined by the clinician. The recommended depth of the abutment margin for posterior teeth was 0.5mm, for anterior teeth 1mm, and placement of the lingual margin of the abutment was at the height of tissue (Figures 9 and 10). The information relating to the abutment design was transferred to a milling machine and the abutments were milled from a titanium block. The abutments were then placed on the master model and returned to the clinician for try-in (Figures 11 and 12).

Verification

Abutments were placed in each specific site based upon the acrylic transfer index, which designated the orientation of each abutment as it related to the arch. Radiographs were made to verify the seating of all of the abutments. Because these abutments were fabricated



Figures 9 and 10: The recommended placement of the lingual margin of the abutment was at the height of tissue



Figures 11 and 12: The abutments were placed on the master model and returned to the clinician for try-in

with computerised landmarks, the tissue response and position circumferentially was very predictable (Vafiadis DC, 2007). Tissue position on the facial, lingual, mesial and distal was calculated by the computer and, during the design phase, positioned as designated by the clinician (Figure 13). The recommended position in the maxillary posterior region was 0.5mm below tissue level.

The new occlusion rim was fabricated for use to fit over the abutments so that final facebow transfer, VDO and midline positions could be recorded. The midline was verified and facebow transfer was made. Tooth selection and position were verified. In addition, the original VDO reference position was measured and replicated in the new denture try-in. Evaluation was made at this point for lip support, phonetics, occlusion, VDO and patient approval. After final approval, models were made from this provisional and used in the laboratory for various procedures and

for the final fixed ceramo-metal prosthesis position (Figures 14 and 15).

Framework

This information facilitated the transfer of the teeth position to the original abutment master model. An insical index was made from a putty matrix and this served as the guide for the ceramo-metal framework preliminary wax form. Using the cutback technique, a proper tooth alignment was created. This ensured that the position determined by the previous denture base would be replicated through to the wax design. Once all of the insical positions had been verified, proper ceramic support was created to ensure even distribution of ceramic material throughout the prosthesis. Once this was confirmed, it was cast with high noble metal (64% gold). It was fitted onto the abutments on the original master model, trimmed and polished (Figures 16 to 22).

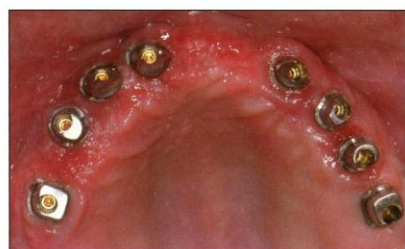
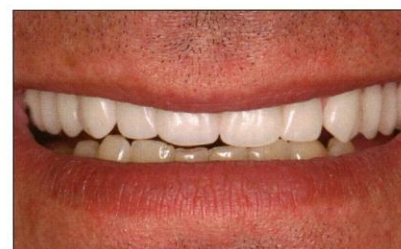
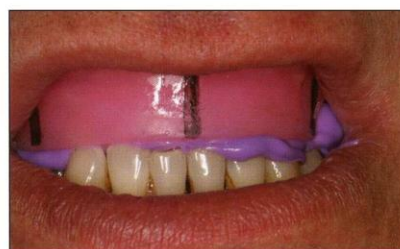Figure 13: Tissue position on the facial, lingual, mesial and distal was calculated by the computer and then designated by the clinician



Figures 14 and 15: Once all of the relevant factors had been approved, models were made to help with the final, fixed ceramo-metal prosthesis position

Final placement

Final placement of the abutments using a torque driver to 25Ncm, sealed with cotton balls and flowable composite (LuxaFlow, DMG), was accomplished. The framework was tried in and radiographs taken. After it was confirmed that the castings adequately fit the abutments, a final VDO record was made from the metal framework to the opposing dentition with a rigid bite registration material (Regisil, Dentsply). The measurements from the original reference points were repeated, confirming the final working VDO. A final pick-up impression with polyvinyl impression material was made (Impregum, ESPE) for final facebow transfer (Artes) and mounting (Figures 23 to 26).

Occlusion

Porcelain bis-bake was achieved with the proper mounting position. Hard tissue pink porcelain was used to enhance aesthetics and mimic natural looking contours and anatomy. Occlusion contacts in centric position were confirmed to the original VDO recorded during treatment. Working movements and canine disocclusion were confirmed and replicated in line with the final diagnostic denture set up. After first try in, the occlusion analysis was confirmed using a computer-generated device (T-Scan III, Tekscan) (Neff AW, 2009).

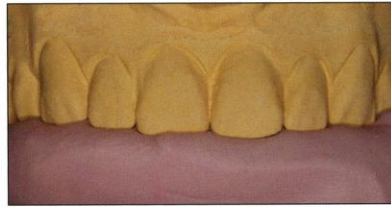

Figure 16: New information enables the transfer of the teeth position to the original abutment master model

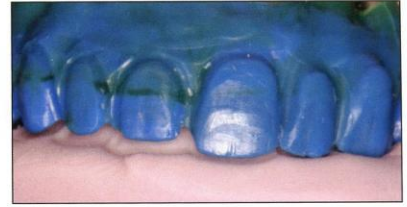
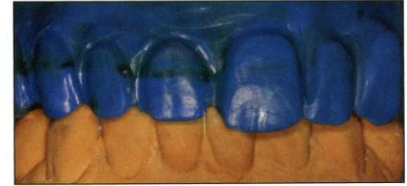
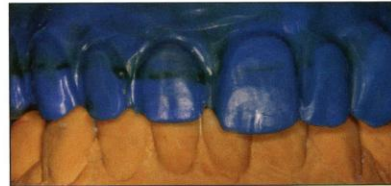Figure 17: An incisal index was made from a putty matrix



Figures 18 and 19: Using the cutback technique, proper tooth alignment was created

Appearance

Final facial aesthetic evaluation and sculpting was performed. In addition, incisal interproximal diskings were performed to create tooth individuality (Figures 27 to 31).

Discussion

Treating the maxillary edentulous area can be difficult unless proper planning is scheduled with the surgeon and the restorative dentist. Using a provisional denture set up will help the clinician to evaluate the facial vertical

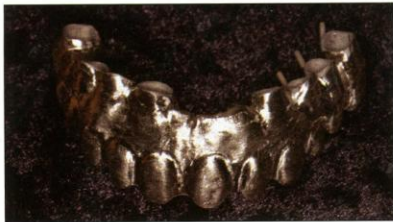
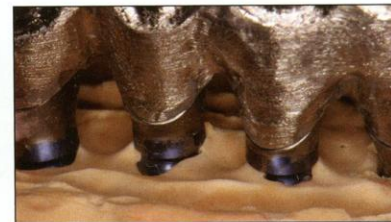
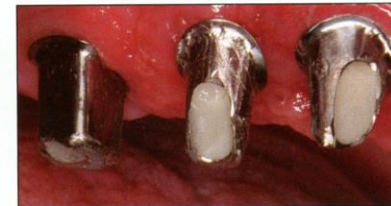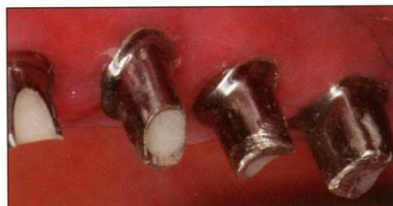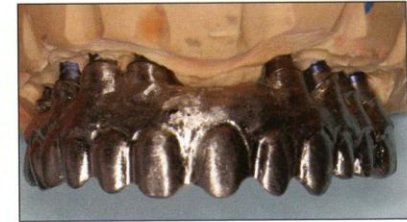Figure 20: Once even distribution of ceramic material throughout the prosthesis was confirmed, it was cast with high noble metal



Figures 21 and 22: The prosthesis was fitted onto the abutments on the original master model, trimmed and polished



Figures 23 and 24: Final placement of the abutments using a torque driver to 25Ncm was accomplished

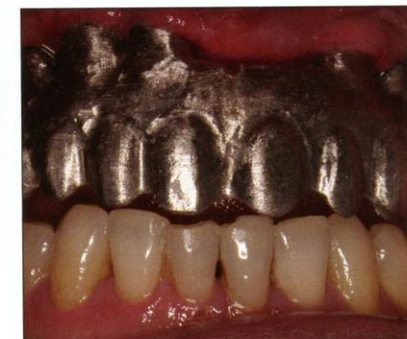

Figure 25: The framework was tried in

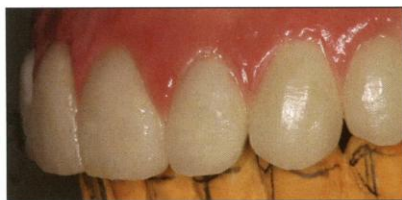

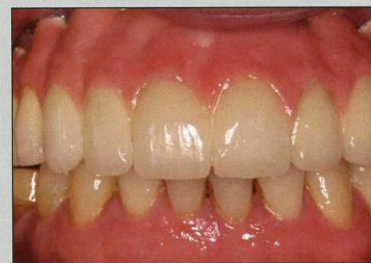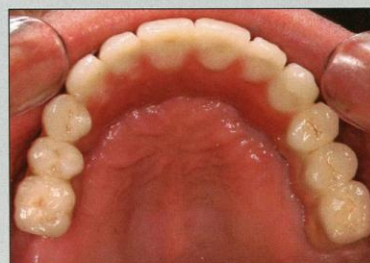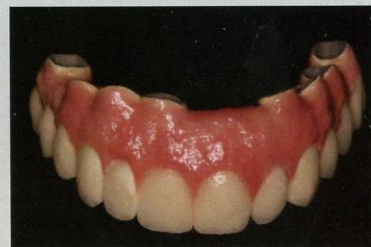
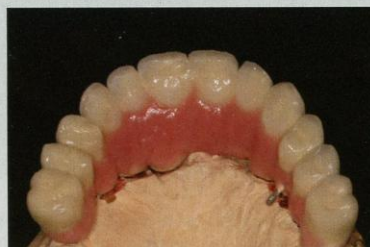Figure 26: A final VDO record was made from the metal framework to the opposing dentition with a rigid bite registration material

dimension, incisal edge position and placement of the implants based on the lip support, and develop the angulation of placement so that an immediate provisional can be placed. Using a rigid fixed position to determine the working vertical dimension and repeating this measurement throughout the treatment may be more accurate than extra-oral markings on the face. Using computerised abutments to relate the placement of the implants and final abutments is beneficial. Anecdotaly, the tissue response is very favourable with these abutments, and the tissue change after placement is minimal. Avoiding impression copings and repeated removal of healing abutments may preserve the integrity of the tissue and prevent recession.

Final aesthetics for implant restorations depend upon proper vertical dimension of occlusion and filling out the buccal corridor, which is sometimes difficult.

The use of hard tissue replacement and pink porcelain will also enhance the aesthetic result.

Using canine guidance and posterior disocclusion during working movements will reduce muscle clenching, similar to that of bite plate therapy. This may also prevent the porcelain fracturing during mastication.



Figures 27 to 31: Final facial aesthetic evaluation and sculpting was performed. In addition, to create individuality between the teeth, incisal interproximal disking was performed



References

- Ganeles J et al (2001) Immediate loading of implants with fixed restorations in the completely edentulous mandible: report of 27 patients from a private practice. *Int J Oral Maxillofacial Implants* **16**: 418-426
- Hunt P, Ararat Y (2006) Immediate transition to an implant supported dentition. *Compend Contin Educ Dent* **27**(4): 254-262
- Jaffin RA, Kumar A, Berman CL (2000) Immediate loading of implants in partially and fully edentulous jaws. A series of 27 case reports. *J Periodontol* **71**: 833-838
- Liu CLS (2005) The impact of osseointegrated implants as an adjunct and alternative to conventional periodontal prosthesis. *Compend Contin Educ Dent* **26**(9): 653-667
- Neff AW (2009) Using computerized occlusal analysis. *Inside Dentistry* **5**(1): 80-81
- Ortial JP (1995) Vertical dimension and therapeutic choices. *American Journal of Orthodontics and Dentofacial Orthopedics* **108**(4): 432-441
- Preston JD (1979) A reassessment of mandibular transverse horizontal axis theory. *JPD* **41**(6): 605-613
- Romanos GE (2003) Treatment of advanced periodontal destruction with immediately loaded implants and simultaneous bone augmentation: a case report. *J Periodont* **74**(2): 255-261
- Saoudon AP (2004) Immediate implant placement and temporization: literature review and case studies. *Compend Contin Educ Dent* **25**(4): 277-292
- Salama H, Rose LF, Salama M, Betts NJ (1995) Immediate loading of bilaterally splinted titanium root-form implants in fixed prosthodontics – a technique re-examined. Two case reports. *Int J Period Rest Dent* **15**: 344-361
- Sullivan DY et al (1996) The reverse-torque test: a clinical report. *Int J Oral Maxillofacial Implants* **11**: 179-185
- Tarnow DP, Emtiaz S, Classi A (1997) Immediate loading of threaded implants at stage 1 surgery in edentulous arches; ten consecutive case reports with 1-5 year data. *Int J Oral Maxillofacial Implants* **12**: 319-324

Using computerised abutments may give the clinician a more accurate and predictable way to fit abutments and try in metal/ceramic prostheses. **1**

Additional notes

In the past three years, since the completion of this patient's treatment, the digital acquisition technology has advanced (see Figures 32 to 35). Today we can also scan the coded abutments and transfer the information directly to the implant companies through electronic files. This technology saves additional time and money for all parties. These digital programs are now being married together to serve clinicians and patients more effectively. The design technician is also given more information, improving the design of the CAD/CAM abutments. During the design phase, we are providing them with a digital radiograph to help see the bone levels and the tissue biotype, for a better understanding of the tissues' ability to be displaced. We are also giving the design technician an algorithm equation called 'Finding Z', which helps to predict the tissue displacement through a mathematical equation. To acquire this equation, please email the author at drdean17@aol.com.

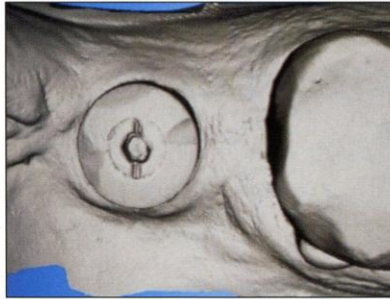


Figure 32: Cerec Blue-cam intra-oral scan of an Encode coded abutment

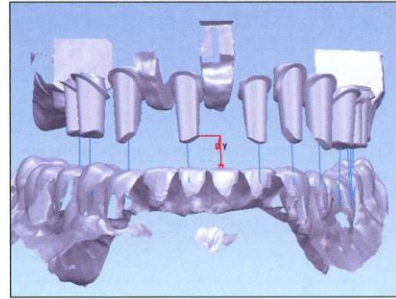


Figure 33: Digital design of full arch Encode abutments

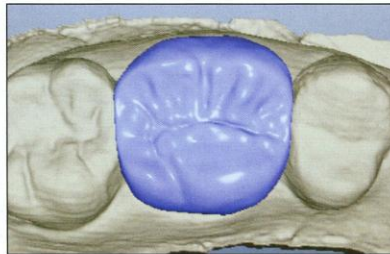


Figure 34: E4D digital design of a molar on an Encode implant abutment

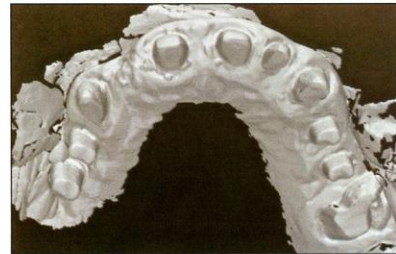


Figure 35: 3M Lava intra-oral scan of a full arch of implants and teeth

Redefining

the boundaries in Implant Dentistry

With Dental and Facial aesthetics in mind, Swann-Morton have produced this versatile range of handles and blades.

The cutting edge expertise embodied within the Swann-Morton Fine Range meet the most demanding and complex requirements presented by modern day Periodontal, Cosmetic, Oral Implantology, and Maxillofacial procedures.

Where only Swann-Morton will do.

For more information on the Swann-Morton range of products designed for Dentistry, including the lightweight Fine Range, please go to our website

Swann-Morton



Owlerton Green, Sheffield S6 2BJ
Telephone: 0114 2344231, Sales: 0114 2344223,
Fax: 0114 2314966

uksales@swann-morton.com,
exportsales@swann-morton.com
www.swann-morton.com

www.swann-morton.com

'Swann-Morton' and the 'Ring Pattern Logo' are the registered trade marks of Swann-Morton Limited and related companies.